

## The transition from RGB to multispectral fundus imaging

Antonio Calcagni  
<http://www.vision.inst.ac.uk/~ss>

School of Life and Health Sciences  
Aston University  
Birmingham, UK

The eye is unique in the human body as it allows direct, non-invasive inspection of tissue within the ocular cavity (lens, vitreous, retina and choroid). The fundus of the human eye is a complex multi-layered structure, with a high level of variability according to genetic, ethnical, and pathological factors and the highly vascularised tissue of the retina and choroid frequently gives an insight on the general state of the vascular system of the rest of the body.

Image formation in fundus photography is determined by the histology of the tissue and the wavelengths being used. Standard fundus imaging utilises red, green and blue channels: as each channel comprises a broad spectral band, this implies not only that useful information may be lost secondary to the lack of spectral detail, but also that useless information may obscure important signs. Traditional fundus imaging therefore frequently fails to yield the amount of information (both at a local and a systemic level) that is effectively available from the fundus.

The image analysis challenge is to generate a statistical model of the healthy human fundus across a range of narrow band wavelengths and establish methods of regional fundus analysis, enabling to identify the spectral characteristics of the normal fundus. This will pave the way to algorithms that link spectral abnormalities to specific pathological conditions and eventually produce a screening and diagnostic tool that will aid clinicians in hospitals and the high street in their decision making process.

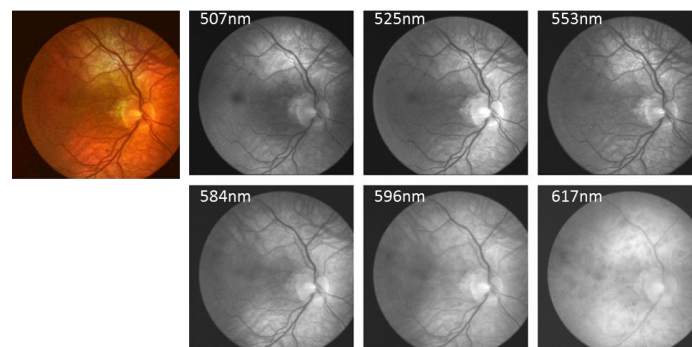


Figure. Left: colour image of a healthy fundus; Right: Multispectral image set of the same fundus showing details at wavelengths 507, 525, 553, 584, 596 and 617nm.