

Age-related Macular Degeneration Identification In Volumetric Optical Coherence Tomography Using Decomposition and Local Feature Extraction

Abdulrahman Albarrak¹
A.Albarrak@liverpool.ac.uk
Frans Coenen¹
<http://www.csc.liv.ac.uk/~frans/>
Yalin Zheng²
<http://pcwww.liv.ac.uk/~yzheng>

¹ Department of Computer Science
University of Liverpool
Liverpool, UK

² Department of Eye and Vision Science
University of Liverpool
Liverpool, UK

Abstract

In this paper we proposed a decomposition based approach, coupled with local feature extraction, to support the analysis of Three-Dimensional (3D) Optical Coherence Tomography (OCT) images so as to determine the presence (or otherwise) of Age-related Macular Degeneration (AMD) in the retina of the human eye. AMD is one of the leading causes of vision loss in people aged over 50 years in the world. The 3D OCT imaging technique has become an indispensable diagnostic tool for the management of AMD. However, there is a lack of automated decision-making tools for analysing the large volumes of data that can be collected using OCT. In order to address this problem, a volumetric analysis technique is proposed for the automated diagnosis of AMD in 3D OCT images without the need for detecting AMD lesions. The process commences with the decomposition of a given image into sub-regions by recursively dividing a volume into sub-volumes. Then, for each sub-volume, *oriented gradient local binary pattern histograms* are extracted and formed into a feature vector to which classifier generation techniques can be applied. The proposed technique was evaluated using ten-fold cross validation by applying it to 140 volumetric OCT images, the results demonstrated a promising performance with a best Area Under the receiver operating Curve (AUC) value of 94.4%.

1 Introduction

One of the most currently advanced Three-Dimensional (3D) imaging techniques is Optical Coherence Tomography (OCT) invented by Huang *et al.* [4]. OCT makes use of low-coherence light and ultrashort laser pulses in order to detect the spatial position of tissue and resolve depth information. The use of light waves enables acquisition of images (volumes) with very high resolution that can reveal precise details of internal structures. 3D cross-sectional volumes are generated from a series of 2D “slices” often referred to as B-scans.

© 2013. The copyright of this document resides with its authors.
It may be distributed unchanged freely in print or electronic forms.

In the past decade, OCT has found success in the diagnosis of various eye diseases one of which is Age-related Macular Degeneration (AMD).

AMD is a macular disease that can result in severe vision loss in people aged 50 years or over. This disease damages the retina causing retinal pigment epithelium atrophy, detachment and other abnormalities such as drusen and fluid inside the retina [5]. So far OCT is the only imaging technique that can show the cross-sectional details of the retina and choroid, where most of the AMD indicators can be clearly seen. AMD is typically identified in retinal OCT images by visual inspection. A normal retinal volume has smooth and connective tissue layers while an AMD retinal volume has disrupted layers and other abnormal patterns. Figure 1(a) shows a 3D OCT normal retinal image; the retina has a smooth contour and a regular arrangement of individual retinal layers. Figure 1(b) shows a 3D OCT retinal image with AMD showing the abnormal change in the retina associated with AMD where fluid and detachment of the retina causes the layers of the retina to separate from one another.

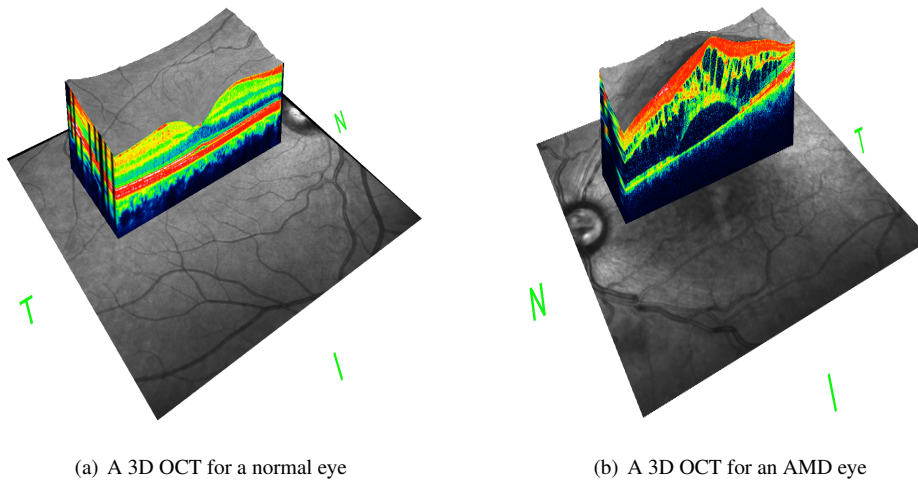


Figure 1: Examples of two 3D OCT images showing the difference between a “normal” and an AMD retina.

With the widespread use of 3D OCT techniques, various challenges and advantages have been identified. Many clinicians nowadays are overwhelmed by the large number of patients and the amount of image data collected for each of them. They are limited by time and resources. There is also a lack of automated analysis tools and most of the existing tools used for thickness measurement other image processing analysis. In practice, subjective assessment is the mainstay. Usually clinicians will simply “skim” through all the image data associated with a patient so as to arrive at a decision. Although the clinicians do an outstanding job the process is subject to human error and skill. Therefore automated analysis tools, such as that proposed in this paper, are desirable; not only to provide for better patient management but also to provide for training.

We propose a method for automatically identifying AMD in 3D OCT images of the form shown in Figure 1. The novel element of the proposed method, in the context of image volumes, is that it combines oriented gradient and Local Binary Pattern (LBP) histograms with a decomposition based method in order to generate an effective volumetric representation.

The remainder of this paper is divided into four sections. In section 2, some previous work related to the classification of OCT data and other feature extraction methods is presented. The proposed approach is then described in section 3. In section 4 we assess the proposed method by reporting some evaluation results conducted using ten-fold cross validation. In the final section, Section 5, the implication of using the proposed method is discussed and some conclusions drawn.

2 Related Work

Work on 3D volumes has been mostly directed at statistical feature extraction and representation. Examples include: (i) Local Phase Quantization (LPQ) and (ii) the Local Binary Patterns (LBP). LPQ relies on the local Fourier transform (at low frequency) where by a histogram of the quantised Fourier transform is computed [8]. LBPs compute the relationship between a pixel and its immediate neighbours. With respect to 3D, however, the generation of 3D rotation invariant LBPs are computationally expensive. Zhao and Pietikainen [9] proposed the use of Three Orthogonal Planes LBPs (LBP-TOP). The LBP-TOP representation considers the calculation of LBPs only with respect to neighbouring voxels located in the XY , XZ and YZ planes.

There have been a number of reported studies with respect to macular disease diagnosis using OCT images, but mainly focused on 2D OCT image analysis. For example a study conducted by Liu *et al.* [6] implemented a classifier for identifying retina diseases, including AMD, using 2D retinal OCT image slices. The classifier generation process comprised three steps. The first step consisted of image processing and alignment. A threshold and median filter was applied in order to remove noise. Following this, a morphological operator was used to remove unwanted objects. A least square filter was then used to both extract the retina region while at the same time “flattening” it. In the second stage, the pre-processed image was represented using a “Multi-Scale Spatial Pyramid” (MSSP) with different levels. Each level in the MSSP comprised a local description in terms of a histogram of the LBPs. Dimensionality was reduced by the means of Principal Component Analysis (PCA). All the LBPs were then combined to form a global feature descriptor. Finally, the Radial Basis Function (RBF) kernel based Support Vector Machine (SVM) classifier was then applied to the global descriptor to obtain a retinal disease categorisation.

3 Proposed Approach

The proposed method comprises two steps. First, due to the nature of the image acquisition, images of different eyes usually have different orientation and some inherent “speckle” noise. In order to improve the image quality, pre-processing of the retinal volumes is performed to extract a Volume Of Interest (VOI) encompassing the retina and then to flatten the retina (warping). Secondly a features extraction method is applied to the pre-processed volume so as to identify a set of local histogram based feature vectors. The generated feature vectors are then used to train a classifier (a Bayesian network classifier was used with respect to this paper). Each step is considered in further detail in the following two sub-sections.

3.1 Volume Pre-processing

During the OCT scanning of the retina, there are some practical issues that affect image quality. One issue is noise due to fluid in the retina and/or the limitations of OCT scanning. Another issue is that volumetric retinal images are typically not referenced to the same horizontal plane due to the curved shape of the retina and variability across populations. In this case, the retinal image must be flattened before any further processing can take place.

Thus two important tasks are: (i) identification and extraction of a Volume Of Interest (VOI) which also results in noise removal, and (ii) flattening of the retina as appropriate. A hybrid approach is proposed that combines the use of the Split Bregman Isotropic Total Variation algorithm [2] with a least-squares approach [6]. The Split Bregman method is applied to every slice of the 3D volume to extract the VOI, the retina, in such way that noise is also removed. Then the image is flattened using a second order polynomial least-square curve fitting according to the nature of the mean surface of the retina (defined according to the top and bottom retina surfaces). In order to do this we select the slice where the top and bottom surfaces of the volume (retina) are furthest apart and consider these two layers in terms of two vectors made up of voxel values. These two vectors are used to define the “middle” vector which is then used as a reference for flattening the entire retinal volume. Figure 2 shows a set of 2D slices of a retinal image before and after pre-processing.

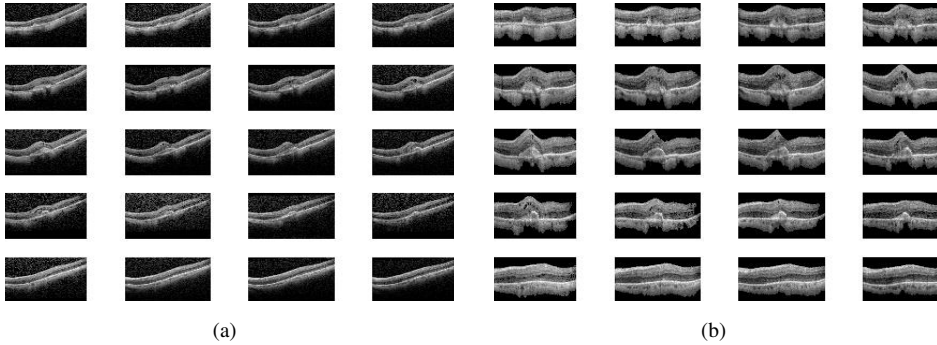


Figure 2: Illustration of the pre-processing: (a) the original image, and (b) after pre-processing

3.2 Local Feature Extraction and Classification

In order to extract the desired local features, we applied two steps. First, given a pre-processed volume, we decomposed the volume into a set of sub-volumes (32 in total). For every sub-volume, the LBP-TOPs were computed [9]. Recall (Section 2) that the LBP-TOP representation considers LBP codes in terms of three planes namely XY , XZ and YZ . The LBP histograms of the three planes (XY , XZ and YZ planes) were concatenated. Both a “normal” LBP histograms and a Histogram of Oriented Gradients (HOG) for LBP-TOP codes were generated with respect each plane and each sub-volume (thus six histograms per sub-volume, 192 histogram bins in total). In order to form a HOG [1, 7] from the three LBP-TOP representations (XY , XZ and YZ), the image gradients ∇_x , ∇_y , ∇_z were first computed using a convolution filter with a vector $v = [-1, 0, 1]$. Then the inverse tangent was computed

Method	Precision	F-score	Acc.	Sensit.	Specif.	AUC
1. MSSP based	81.9	85.9	85.7	82.4	89.4	90.4
2. LBP-TOP based	88.2	87.6	87.8	87.0	88.7	91.0
3. LPQ based	80.9	83.3	84.3	87.0	88.7	88.0
4. proposed method	91.5	91.4	91.4	92.4	90.5	94.4

Table 1: Comparison of proposed method with methods based on MSSP, LBP-TOP, LPPQ (best results highlighted in bold font).

first between the ∇x and ∇y gradients forming *angle1*, and then between the result and the ∇z forming *angle2*: $angle1 = atan2(\nabla x, \nabla y)$ and $angle2 = atan2(\nabla z, \sqrt{\nabla x^2 + \nabla y^2})$. The magnitude of each sub-volume’s gradients is then calculated using $magnitude = \sqrt{(\nabla x^2 + \nabla y^2 + \nabla z^2)}$. The HOGs were generated by considering each set of angles (in each plane and each sub-volume) and their accumulated magnitudes. The HOG were set to be $27*B$ bins (range of $27 (3*3*3)$ degrees per bin) where the angle within the range of $\pi + 2/B$ to $2 \times \pi/B$: π were considered ($B=9$). If the angle is within the range of the angle, then the *magnitude* was accumulated for the histogram bin. Then the complete set of histograms are normalised. Each histogram is conceptualised as a vector. The final image description will then be formulated by appending these vectors to one another to create a single feature vector (one per image). To reduce the number of elements in this eventual feature vector Principal Component Analysis (PCA) was applied so that a summarising total feature vector was derived. Each resulting feature vector was combined with a class label indicating the disease status of the associated retinal volume as informed by medical retina experts. A Bayesian network classifier was then used to categorise the feature vectors [3]. The results will be presented in the next section.

4 Evaluation

To evaluate the effectiveness of the proposed approach experiments were conducted using 140 3D OCT volumes, 68 “normal” and the remainder AMD. The size of each volume was about $(1024 \times 496 \text{ pixels}) \times 19$ slices describing a $6 \times 6 \times 2$ mm retinal volume. Ten-fold cross validation was used to evaluate the proposed method. Six parameters were used to measure the performance of the proposed algorithm: precision, f-score, accuracy, sensitivity, specificity and AUC.

A comparison between the proposed method and a number of existing methods was conducted. Table 1 compares the results obtained with the 2D MSSP method [6] and two 3D representation methods: LBP-TOP [9] and LPQ [8]. Bayesian classifier generation was used in all cases. From the table it can be seen that the proposed method outperformed the other methods. The MSSP method [6] generated an AUC of 90.4 while the AUC for the proposed method is 94.4. With respect to the other 3D based method, the AUC of LBP-TOP is 91.0 while LPQ is 88.0.

5 Discussion and Conclusion

The aim of the study presented in this paper was to build a diagnostic system that can be applied to 3D OCT retinal volumes so as to perform a binary classification of these vol-

umes in terms of AMD (AMD vs. non-AMD). To address this problem a new method was proposed that combines the concept of volume decomposition and LBPs. The results obtained using the proposed technique demonstrated a good performance in comparison with other 3D (LBP-TOP, LPPQ) methods and a 2D based method (MSSP). The most significant findings to emerge from the work is that the combination of image decomposition and LBP histograms helps to form an accurate feature descriptor for classification purposes. A number of possible future studies using the same experimental set up are envisaged. It would be interesting to assess the effects of applying frequency decomposition based methods, such as curvelets, for extracting salient features describing sub-regions. It would also be interesting to take into consideration other ways of representing images, such as intensity frequency time series. Alternatively, hybrid representations may be considered so as to, for example, better understand the relationships between intensity frequencies and spatial information.

References

- [1] N. Dalal and B. Triggs. Histograms of oriented gradients for human detection. In *Computer Vision and Pattern Recognition, 2005. CVPR 2005. IEEE Computer Society Conference on*, volume 1, pages 886–893, june 2005.
- [2] Tom Goldstein, Xavier Bresson, and Stanley Osher. Geometric applications of the split bregman method: Segmentation and surface reconstruction. *Journal of Scientific Computing*, 45(1-3):272–293, 2009.
- [3] Mark Hall, Eibe Frank, Geoffrey Holmes, Bernhard Pfahringer, Peter Reutemann, and Ian H. Witten. The weka data mining software: an update. *SIGKDD Explor. Newsl.*, 11(1):10–18, November 2009.
- [4] D Huang, EA Swanson, C P Lin, JS Schuman, WG Stinson, W Chang, MR Hee, T Flotte, K Gregory, CA Puliafito, and al. et. Optical coherence tomography. *Science*, 254(5035): 1178–1181, 1991.
- [5] Rama D. Jager, William F. Mieler, and Joan W. Miller. Age-related macular degeneration. *New England Journal of Medicine*, 358(24):2606–2617, 2008.
- [6] Yu-Ying Liu, Mei Chen, Hiroshi Ishikawa, Gadi Wollstein, Joel S. Schuman, and James M. Rehg. Automated macular pathology diagnosis in retinal oct images using multi-scale spatial pyramid and local binary patterns in texture and shape encoding. *Medical Image Analysis*, 15:748–759, 2011.
- [7] O. Ludwig, D. Delgado, V. Goncalves, and U. Nunes. Trainable classifier-fusion schemes: An application to pedestrian detection. In *Intelligent Transportation Systems, 2009. ITSC '09. 12th International IEEE Conference on*, pages 1–6, oct. 2009.
- [8] Juhani Päivärinta, Esa Rahtu, and Janne Heikkilä. Volume local phase quantization for blur-insensitive dynamic texture classification. In *Proceedings of the 17th Scandinavian conference on Image analysis, SCIA'11*, pages 360–369, Berlin, Heidelberg, 2011. Springer-Verlag.
- [9] Guoying Zhao and M. Pietikainen. Dynamic texture recognition using local binary patterns with an application to facial expressions. *Pattern Analysis and Machine Intelligence, IEEE Transactions on*, 29(6):915–928, june 2007.