

# Non-rigid 2D-3D image registration for use in Endovascular repair of Abdominal Aortic Aneurysms.

Ali Raheem<sup>1</sup>  
ali.raheem@kcl.ac.uk

Tom Carrell<sup>2</sup>  
tom.carrell@gstt.nhs.uk

Bijan Modarai<sup>2</sup>  
bmodarai@doctors.org.uk

Graeme Penney<sup>1</sup>  
graeme.penney@kcl.ac.uk

<sup>1</sup> Imaging Sciences, King's College London, Strand, London WC2R 2LS

<sup>2</sup> Dept. of Vascular Surgery, St Thomas' Hospital, Westminster Bridge Road, London SE1 7EH

---

## Abstract

Ruptured abdominal aortic aneurysms are a relatively common cause of death in the western world. Endovascular repair can be used to reduce the risk of rupture and is becoming the preferred method of treatment in lieu of open surgery. However, intraoperatively only 2D fluoroscopy imagery is available to the surgeon making complex repair difficult. We have been investigating the use of a rigid 2D-3D registration system which enables information from the CT to be overlaid onto the fluoroscopy images during the procedure. The main limitation of this method is that the rigid interventional instruments deform the aorta. This paper investigates the use of manually picked landmarks and the thin plate spline algorithm to deform the CT surface so it more accurately represents the interventional scene. Experiments are carried out on data from eight patients. Results show that the mean error in visceral ostia positions can be reduced from  $4.7\text{mm} \pm 2.9\text{mm}$  (mean  $\pm$  standard deviation) to  $2.7 \pm 1.2\text{mm}$  and  $3.2 \pm 1.4\text{mm}$  for intra-observer and inter-observer guided deformation respectively.

## 1 Introduction

### 1.1 Motivation

Abdominal aortic aneurysm (AAA) are dilations of the aortic wall exceeding 50% of the normal aortic diameter, and once it reaches 55mm intervention is considered. Open surgery carries a significant risk of early and postoperative mortality. Endovascular repair of aortic aneurysm (EVAR) offers a minimal invasiveness lower risk procedure.

The EVAR procedure is simple in principle. A stent is selected depending on the aneurysm and access is achieved to the aneurysm via the femoral arteries and is guided via a catheter down a stiff wire to the location and deployed under fluoroscopy. However, this simple principle is complicated by an often tortuous aorta and access vessels. In aneurysms with a short

neck below the renal arteries fenestrated endovascular repair is an option that requires accurate deployments of endovascular stents into the visceral vessels. This has the additional complication that semi-deployed devices can often cover the ostia of vessels, making their intraoperative visualisation with contrast media impossible. These clinical requirements have led us to investigate the potential for using a 2D-3D guidance system to overlay a surface rendering of the aorta, from the preoperative computed tomography (CT) image, onto the fluoroscopy during the intervention. The current system matches on a vertebra, and assumes a rigid body relationship exists between the aorta and vertebra. However, this assumption can be violated especially with the introduction of stiff endovascular tools. While simple cases can often be performed even with these discrepancies we believe that complex cases require that the imagery accurately reflects the intraoperative anatomy. In order to address these issues the performance of a non-rigid 2D-3D image registration is investigated, and its effectiveness in predicting the location of the renal ostia evaluated and compared to the rigid algorithm.

## 1.2 Literature Review

Previously 2D-3D registration has been considered to aid EVAR, however, in its infancy only simple EVAR cases were attempted and sophisticated image guidance was not deemed necessary [2]. Only with the recent success of the procedure has interest in complex repair warranted research into more elaborate image guidance.

Similar rigid registration systems to aid EVAR have been reported [1]. Only a few papers have addressed non-rigid 2D-3D registration. Fleute and Lavallée [3] aligned a statistical shape model of a femur to a few x-ray views. Zheng [6] published a method to find point correspondence between multiple 2D images and a 3D model, again for an orthopaedic application. The recent publication by Groher *et al.* [4] is most relevant to our work as they align vascular structures to a single view using smoothness and length preservation constraints.

## 2 Method

### 2.1 Data

Data is used from eight patients who underwent elective EVAR. Each patient had a preoperative CT scan, and digital subtraction angiography (DSA) sequences obtained at up to three time points during the intervention: with a stiff wire, with the undeployed stent, and after stent deployment, see figure 1. The DSA mask images (which are essentially standard fluoroscopy “spot-film” images) were used for 2D-3D rigid registration while the DSA images were used for non-rigid registration and validation as described in the following sections.

### 2.2 2D-3D Registration Methods

Rigid registration is carried out using the algorithm described in [5]. In brief, this algorithm registers on a single vertebra, the one closest to the visceral ostia. Digitally reconstructed radiographs are produced by casting rays through the CT volume, which are compared to the fluoroscopy image using an intensity based similarity measure, gradient difference. The position and orientation of the CT volume is iteratively altered, using a downhill search strategy, to optimise the similarity measure. The output is a perspective projection transformation

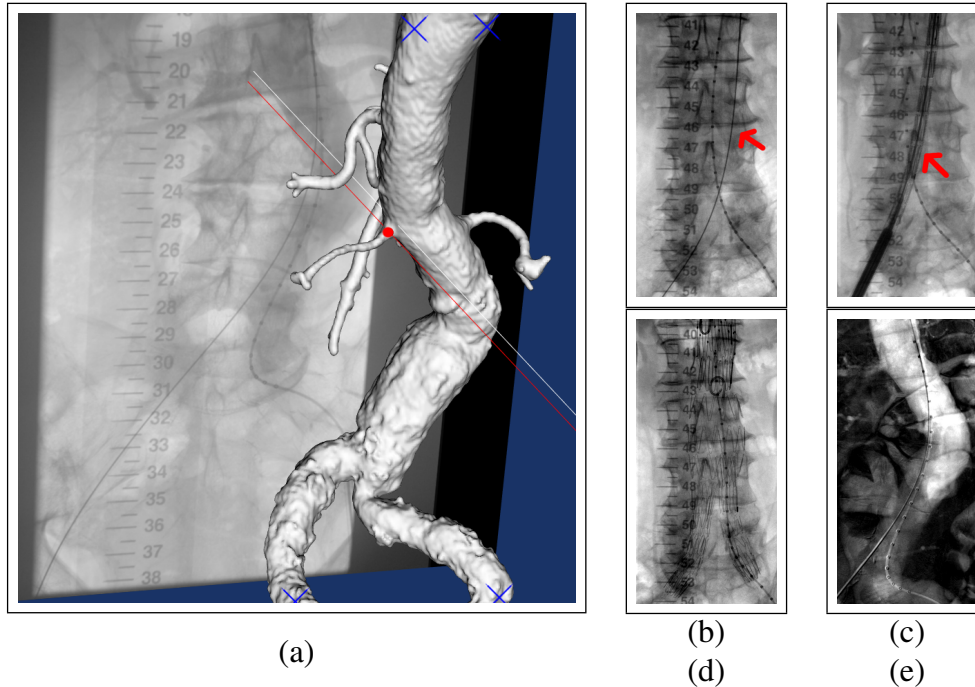


Figure 1: Selecting a moving point (left renal ostia) in the deformation software as the red dot in a), blue crosses are fixed points. A typical surgeons view at the various time points from the fluoroscopy b) with the guide wire only c) showing the undeployed stent d) the deployed stent. A DSA image e) is used to show vasculature and identify ostia positions.

$P$  that can map 3D positions in the CT scan to 2D fluoroscopy positions, or given a 2D point on a fluoroscopy image  $\mathbf{u}$  can define a corresponding 3D line through the CT scan  $L(\mathbf{u}, P)$ .

Our non-rigid registration method assumes that the main cause of deformation is the stiff interventional instruments, and that once one of these instruments is inserted the deformation will remain reasonably constant. Our proposal is to refine the rigid registration based on the first DSA sequence where a stiff instrument is present within the aorta. Our method requires two sets of 3D points to be identified, points which represent anatomical landmarks on the preoperative aorta surface  $\mathbf{x}(i)$ , and points which denote corresponding positions during the intervention  $\mathbf{x}'(i)$  where  $i$  denotes a particular point. These points are picked in the following two ways: Firstly four points, which we refer to as “fixed points” (FPs) are chosen manually on a surface rendered view of the segmented aorta. These were picked on the bifurcation of the common iliacs and the lateral aspects of the aorta 3 cm above the celiac artery, as shown in figure 1. These positions were chosen as they surround the clinical region of interest, they are reasonably easy to identify, and they are believed to remain in a reasonably rigid body relationship with bony anatomy. For the fixed points  $\mathbf{x}'(i) = \mathbf{x}(i)$ .

Secondly two points (the clinical targets – the ostia of the renal arteries), which we refer to as “moving points” (MPs) are chosen by picking the 3D positions as before for  $\mathbf{x}(i)$ . The corresponding positions which represent the interventional scene are determined by picking the ostia of the renal arteries on the first 2D DSA image  $\mathbf{u}(i)$ . Their 3D positions are defined as  $\mathbf{x}'(i) = d_{min}(\mathbf{x}(i), L(\mathbf{u}(i), P))$  where  $d_{min}$  is a function which calculates the closest point on line  $L(\mathbf{u}(i), P)$  to point  $\mathbf{x}(i)$ , see figure 1. These two sets of corresponding points  $\mathbf{x}(i)$  and  $\mathbf{x}'(i)$  are used to define a thin-plate spline deformation (TPS)  $T_{TPS}$  which is used to transform points and to deform the aorta surface segmented from CT.

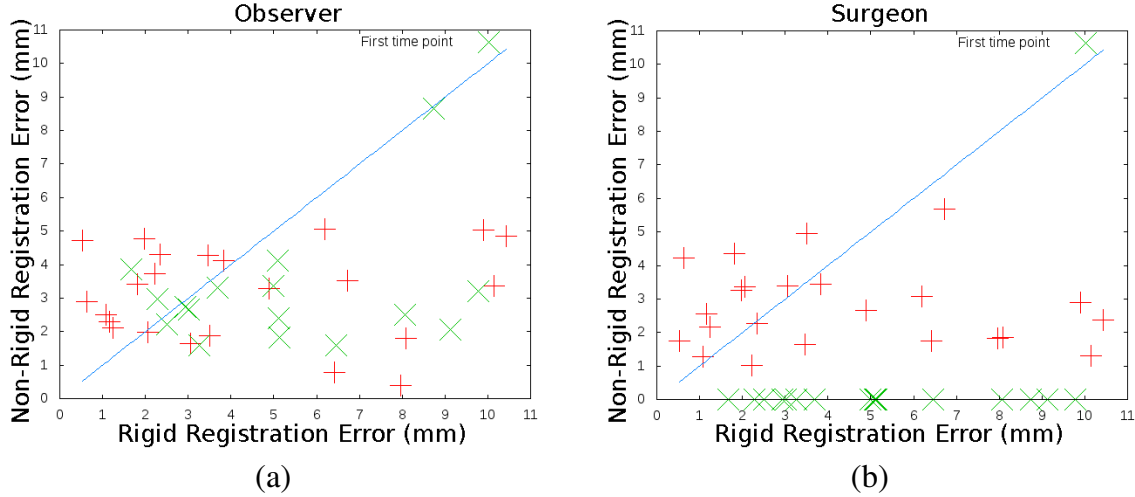


Figure 2: Errors in positions of visceral ostia when rigid registration is used and when non-rigid registration using a) observer picked points or b) points picked by the surgeon.

### 2.3 Experiments and Validation

Our experiments are carried out by non-rigidly transforming the aorta based on information obtained from the first DSA image. Rigid registrations are then carried out to the mask images from the other time points, to obtain a rigid 2D-3D transformation  $P$ . This can be used to project the deformed aorta surface onto each mask image, and onto the associated DSA image for visual inspection of accuracy.

Registration errors were calculated in the following way. Sets of “gold-standard” 2D  $\mathbf{u}_{su}$  and 3D  $\mathbf{x}_{su}$  positions of renal ostia were picked by an experienced surgeon in CT and in all DSA images ( $su$  denotes “surgeon” picked points, compared to  $ob$  for points picked by the independent “observer”). Errors reported are  $d_{min}(\mathbf{p}, L(\mathbf{u}_{su}, P))$ , where  $\mathbf{p}$  represents a 3D point found in one of three ways.

1. Rigid registration error:  $\mathbf{p} = \mathbf{x}_{su}$ .
2. Observer non-rigid error:  $\mathbf{p} = T_{TPS_{ob}}(\mathbf{x}_{su})$  3D ostia “gold-standard” positions are transformed using a non-rigid TPS transformation  $T_{TPS_{ob}}$  calculated by an independent observer using information in the first DSA image, as described in section 2.2.
3. Surgeon non-rigid error:  $\mathbf{p} = T_{TPS_{su}}(\mathbf{x}_{su})$  as point 2, but using a non-rigid TPS transformation  $T_{TPS_{su}}$  calculated using the surgeon picked points from the first DSA image.

## 3 Results

Figure 2 shows the rigid registration error plotted against observer non-rigid error (left) and surgeon non-rigid error (right). Results are separated into those calculated using the first time point  $\times$  (i.e. the time point where the DSA was used for alignment) and results to images acquired at subsequent time points  $+$ . Points which lie below the  $45^\circ$  line show improved accuracy due to non-rigid registration. For the surgeon data all the  $\times$  positions show zero error as these points were used to both calculate the deformation field and for validation. A summary of these results is given in table 1.

Method	Max	Mean	SD
Rigid	10.44	4.70	2.93
Surgeon (excluding first timepoint)	5.68	2.74	1.19
Observer (excluding first timepoint)	5.05	3.16	1.35
Observer (including all timepoints)	8.66	3.11	1.45

Table 1: Overview of results

## 4 Discussion

We have presented a method to account for non-rigid deformation of the aorta in a system which aligns a preoperative CT image to interventional fluoroscopy images for use in complex EVAR. Although, the deformation method is reasonably basic, using manually identified landmarks, it has enabled registration errors to be reduced down from 10mm in some cases, to almost all errors being below 5mm, which approaches our required clinical accuracy of 3-4mm (half a typical renal ostia diameter). This is particularly important, as the cases we believe image guidance will be most useful for are those with very angulated aortas, and it is in these cases which we have observed the most deformation.

It is interesting that the errors recorded by the observer when matching to the first DSA image are not noticeably smaller than the errors to the other time points. This suggests that the main deformation is caused by the insertion of the stiff wire, and after that occurs the aorta remains in a roughly similar position throughout the rest of the intervention.

We are unsure of the cause of the one noticeable outlier in the observer dataset,  $\times$  with 8.7mm non-rigid registration error in figure 2a. In our experiments we did not specify any specific protocol for checking the accuracy of the registration, however, we believe devising and using such protocols are vital for the system to be used routinely in a clinical setting.

## References

- [1] S Eiho, H Imamura, and N Sugimoto. Preoperative and intraoperative image processing for assisting endovascular stent grafting. In *Proc. Informatics Research for Development of Knowledge Society Infrastructure*, pages 81–88, 2004. ISBN 0-7695-2150-9.
- [2] M Breeuwer *et al.* The easi project—improving the effectiveness and quality of image-guided surgery. *IEEE Trans. Tech. Biomed.*, 2(3):156–168, 1998.
- [3] M. Fleute and S. Lavallée. Nonrigid 3-D/2-D registration of images using statistical models. In *Proc MICCAI*, pages 138–147, 1999.
- [4] M. Groher, D. Zikic, and N. Navab. Deformable 2D-3D registration of vascular structures in a one view scenario. *IEEE Trans. Med. Imag.*, 28(6):847–860, 2009.
- [5] G.P. Penney, J. Weese, J.A. Little, P. Desmedt, D.L.G. Hill, and D.J. Hawkes. A comparison of similarity measures for use in 2-D-3-D medical image registration. *IEEE Trans. Med. Imag.*, 17(4):586–595, 1998.
- [6] G. Zheng. A novel 3D/2D correspondence building method for anatomy-based registration. In *Proc. Biomedical Image Registration*, LNCS 4057, pages 75–82, 2006.